

*Research Article*

**MOLECULAR AND PATHOLOGICAL STUDIES OF POST-WEANING  
MULTI-SYSTEMIC WASTING SYNDROME AMONG  
PIGLETS IN KERALA, INDIA**

R. Sairam<sup>1</sup>, B. Dhanush Krishna\*<sup>1</sup>, K. Krithiga<sup>1</sup>, I. S. Sajitha<sup>1</sup>, P. M. Priya<sup>2</sup>, Chintu Ravishankar<sup>3</sup>,  
Mammen J. Abraham<sup>1</sup>

*Received 2 August 2019, revised 28 August 2019*

**ABSTRACT:** Post weaning multi systemic wasting syndrome (PMWS) is an economically important porcine viral associated diseases caused by porcine circovirus 2(PCV2) in weaned piglets worldwide. Recently, the presence of PCV2 was reported in pig population of Kerala. But, PMWS and its association with other pathogens were not explored. Therefore, this study was designed with the objective of screening of 40 piglets for PMWS with concurrent screening for porcine reproductive and respiratory syndrome virus (PRRSV) and porcine parvo virus (PPV). Swine carcasses presented for post-mortem examination with a history of respiratory and reproductive problems collected from February, 2018 to February, 2019 from different parts of Kerala formed the samples for this study. The samples were initially screened with PCR followed by gross, histopathology and immunohistochemical characterisation. Gross lesions observed were mainly generalised icterus in the subcutaneous tissues, non-collapsed lungs, hydrothorax, enlarged bronchial lymph nodes, hepatomegaly with randomly distributed areas of white foci and yellowish colour kidneys. Histopathological lesions revealed broncho-interstitial pneumonia, lymphoid depletion in the germinal centre of the follicles with multifocal areas of granulomatous inflammation in the lymph nodes, lymphoid depletion in the peri-arteriolar lymphoid sheath of the spleen and interstitial nephritis of the kidney. Further, immunohistochemistry (IHC) demonstrated PCV2 antigens mainly in the spleen and lymph nodes. The present study reports three out of four positive PCV2 cases which fulfilled the diagnostic requirements of PMWS. However, PMWS cases were negative for both PRRSV and PPV. Therefore, the present study identified the immunosuppressive nature of PMWS among pig population of Kerala.

**Key words:** PMWS, PCV2, PRRSV, PPV, PCR, Immunohistochemistry.

**INTRODUCTION**

Swine industry is one of the important livestock farming systems, gaining momentum in Kerala with increasing number of small-scale farmers involved in pig production. One of the important challenges faced by the sector is the occurrence of viral diseases especially those affecting the immune system leading to immunosuppression and secondary infections. Porcine circovirus 2 (PCV2) is an economically devastating important emerging viral pathogen of the pig industry throughout the world (Neira *et al.* 2017). PCV2 infection has been linked with porcine circoviral associated

diseases such as post weaning multi systemic wasting syndrome (PMWS), porcine dermatitis and nephropathy syndrome, porcine respiratory disease complex, granulomatous enteritis, reproductive failure, exudative epidermitis and necrotizing lymphadenitis (Ouyang *et al.* 2019).

Among that, PMWS is a multifactorial disease which can cause severe mortality among piglets of age group between 5 to 12 weeks. The disease causes great economic impact due to reduced feed conversion efficiency which leads to decreased weight gain and in terms of expenditure involved in antibiotic usage to control secondary

---

<sup>1</sup>Department of Veterinary Pathology, <sup>2</sup>Department of Veterinary Microbiology, College of Veterinary and Animal Sciences, Mannuthy <sup>3</sup>Department of Veterinary Microbiology, College of Veterinary and Animal Sciences, Pookode, Kerala Veterinary and Animal Sciences University, Wayanad, Kerala, India.

\*Corresponding author. e - mail: dhanush@kvasu.ac.in

infections (Hansen *et al.* 2010). PMWS is often co-infected with other viral pathogens which increase the severity of PMWS (Pallares *et al.* 2002). PCV2 infection in Indian pig population was first described in 2006 (Kumar 2008). A previous study reported the presence of PCV2 infection in Thrissur district of Kerala (Keerthana *et al.* 2016).

Recent reports have suggested that porcine reproductive and respiratory syndrome virus (PRRSV) and porcine parvo virus (PPV) act as important co factors in PCV 2 infection to enhance their severity (Vargas *et al.* 2018, Afolabi *et al.* 2019). But the establishment of PMWS and its co-infection status of PRRSV and PPV have not been explored in the state. Hence, this study focussed on the molecular and pathological studies of PMWS in piglets from different farms with concurrent screening of PRRSV and PPV to establish the presence of these viruses in PMWS cases among the pig population of Kerala.

## MATERIALS AND METHODS

### Collection of Samples

The study was conducted from February 2018 to February 2019 for post mortem examination. Forty piglet carcasses aged between 5 to 12 weeks were selected based on the suspected PCV2 gross lesions such as non-collapsed oedematous lungs, enlarged and congested lymph nodes, hydrothorax and pale to yellowish discoloured liver and kidneys. Complete and detailed necropsies of the carcasses were done with proper recording of gross lesions in different organs. The representative tissue samples from the organs showing gross lesions were collected in 10% neutral buffered formalin and subjected to routine histopathology and immunohistochemistry. Tissue samples such as lungs, tonsils of the soft palate, lymph nodes and spleen were collected in sterile containers and immediately stored at -70°C with proper labelling for molecular study.

### Polymerase Chain Reaction

Total DNA was extracted from the pooled organ tissue samples which were collected from the carcasses suspected for PCV2 using Qiagen D Neasy blood and tissue kit. Sequences of PCV2 primers (Forward primer: 5'CGGATATTGTAGTCCTGGTCG3'; Reverse primer: 5'ACTGTCAAGGCTACCACAGTCA3') and PCR conditions for PCV2 screening were fixed according to the previous literature (Ellis *et al.* 1999). Primers sequences for PPV (Forward primer: 5'AGTTAGAATAGGATGCGAGGAA3'; Reverse primer: 5'AGAGTCTGTTGGTGTATTATTGG3') and

PCR conditions were based on previous work (Aishwarya *et al.* 2016). PRRSV viral RNA was extracted from the tissues using TRIzol reagent (Sigma, USA) followed by conversion into complementary DNA (cDNA) with reverse transcriptase polymerase chain reaction (RT-PCR) as per earlier study with primer sequences (Forward primer: 5'GAGTTTCAGCGGAACAATGG 3'; Reverse primer: 5'GCCGTTGACCGTAGTGGAG 3') as per Jiang *et al.* (2010). The resulting amplicons were analysed on 1.5 % agarose gel after electrophoresis at 80 V for 45 minutes. The PCR product in the gel was documented in a gel documentation system (Bio-Rad Laboratories, USA).

### Histopathology

The representative samples of the organs showing gross lesions such as lungs, lymph nodes, spleen, heart, kidneys were fixed in 10 per cent neutral buffered formalin. Fixed tissues were processed by dehydration, clearing, paraffin impregnation and paraffin embedding. The tissue sections were cut at 4-5 µm thickness and further stained by Haematoxylin and Eosin (Bancroft and Gamble 2008).

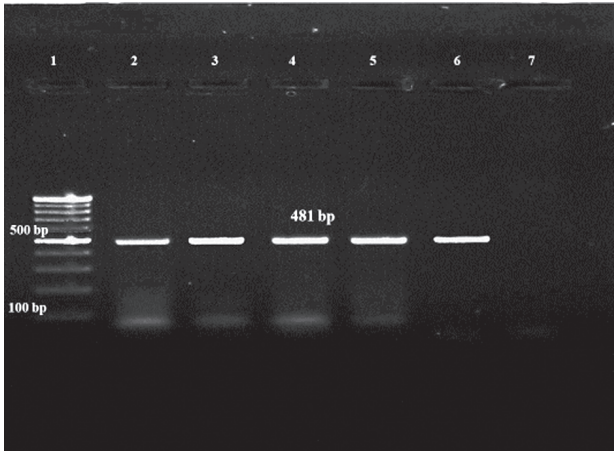
### Immunohistochemistry

Immunohistochemistry was performed for the detection of PCV2 capsid antibody (GeneTex, GTX 128120, USA) with the avidin-biotin complex method (Abcam secondary antibody kit, ab64262, Cambridge, United Kingdom). Tissue sections of lymph nodes and spleen were deparaffinized, rehydrated and antigen retrieval was done using citrate buffer for 95°C for 20 minutes followed by hydrogen peroxide for 10 minutes. After washing with 1% TBST (1% Tris buffered saline tween 20), protein block was carried out for 10 minutes. Primary PCV2 capsid antibody diluted at 1:200 was added to the sections and incubated at 4°C for 16 hours. The sections were washed and incubated with biotinylated goat secondary antibody for 10 minutes at room temperature. Then, the sections were washed with 1% TBST and treated with streptavidin peroxidase for 10 minutes. The sections were washed again with 1% TBST and substrate 3,3'-Diaminobenzidine (DAB) solution was added and incubated for 3 minutes. Mayer's haematoxylin was used as counter-stain for 5 minutes followed by dehydration and mounting with DPX.

## RESULTS AND DISCUSSION

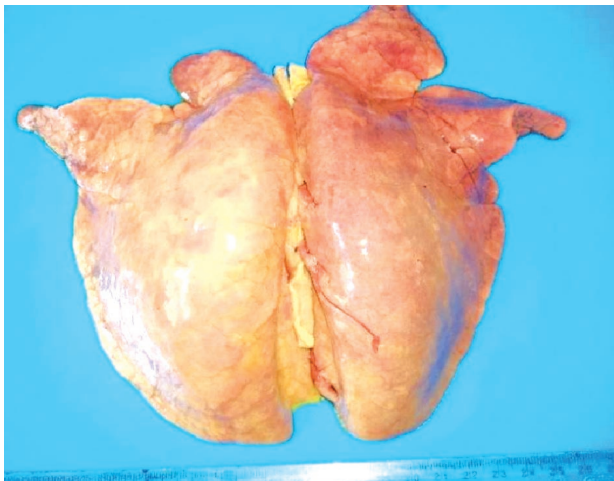
### Detection of PCV2 by PCR

Tonsils of the soft palate, lymph nodes, spleen and heart samples from the carcasses were collected and screened for PCV2 by PCR which amplified 481 bp of

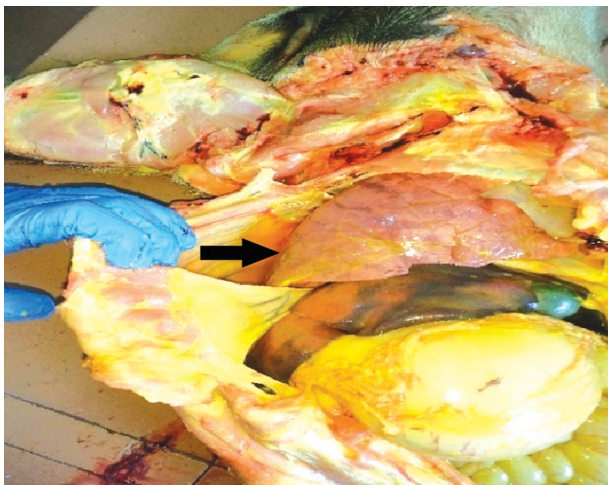


**Fig. 1. Agarose gel electrophoresis showing amplicon of PCV2 DNA encoding 481 bp of ORF2 from tissues using conventional PCR.**

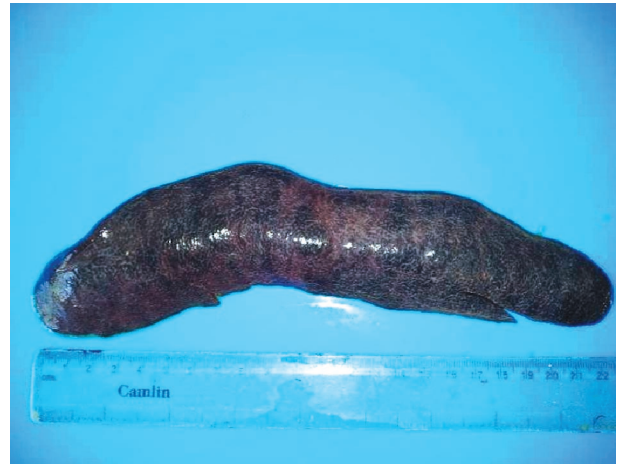[Positive samples showed the molecular size of the 481 bp PCR product. Lane 1. 100 bp DNA molecular markers; Lane 2. Positive control; Lane 3-6. Test samples; Lane 7. Negative sample].



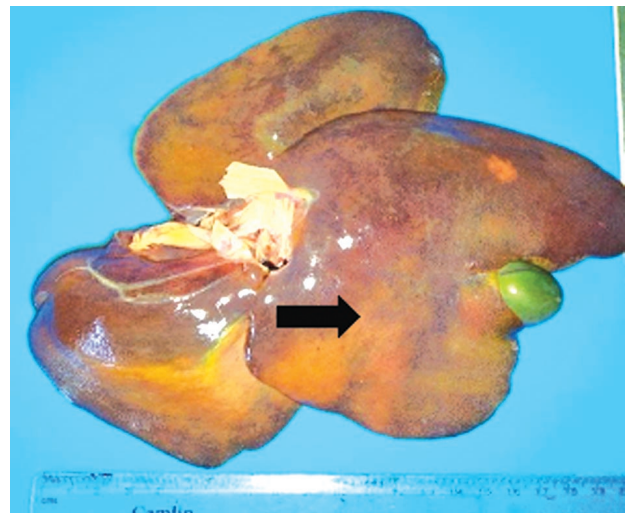
**Fig.2. Non-collapsed, voluminous lungs with cranio-ventral consolidation.**



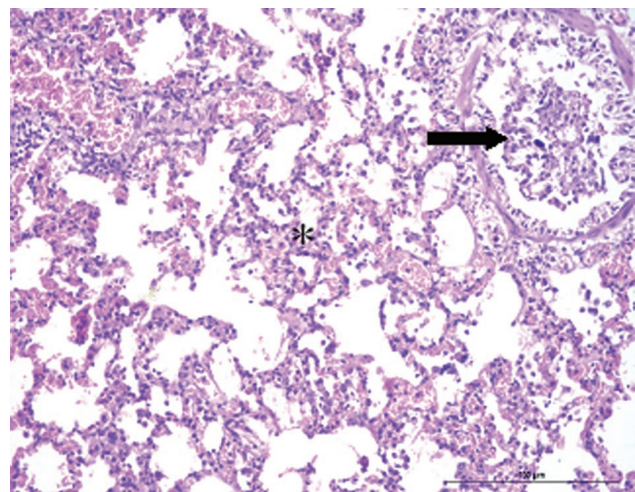
**Fig. 3. Hydrothorax with straw coloured fluid (arrow).**



**Fig. 4. Splenomegaly with congestion.**



**Fig. 5. Diffuse areas of necrosis (thick arrow) and yellowish discoloration of liver.**



**Fig. 6. Lungs: Broncho-interstitial pneumonia characterized by the exfoliation of the bronchiolar epithelium (thin arrow) and thickening of the alveolar septa (asterisk) (H&EX200).**

ORF2 region (Fig. 1). Total of four pigs were positive for PCV2 out of 40 samples analysed. Apart from PCV2, the samples were found negative for PRRSV and PPV by RT-PCR and PCR respectively.

### Gross lesions

The gross lesions displayed in PCV2 affected piglets were generalized icterus over the subcutaneous tissues. Non-collapsed, voluminous lungs had severe consolidation of the cranio-ventral lobes (Fig. 2) and frothy discharge from the air passages of lungs was observed. The bronchial lymph nodes were enlarged and congested. Hydrothorax was characterised by the presence of approximately 70-80 ml of straw-coloured fluid (Fig. 3). Splenomegaly with congestion was seen (Fig. 4). Liver was enlarged, icteric with multifocal areas of necrosis (Fig. 5). Yellowish discolouration of kidneys with randomly distributed areas of white necrotic foci was seen.

### Histopathology

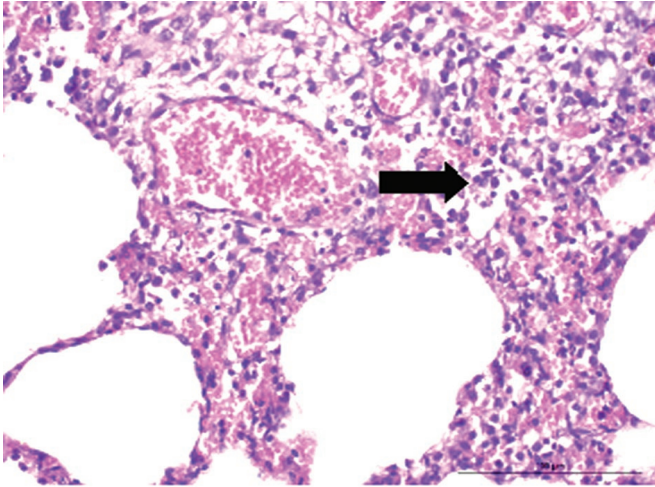
Histopathology revealed interstitial and broncho-interstitial pneumonia characterized by the proliferation of Type II pneumocytes with infiltration of mononuclear cells and desquamation of bronchiolar epithelial cells with congestion of alveolar capillaries (Fig. 6 and Fig. 7). Splenic lesions were mainly moderate to severe depletion of periarteriolar lymphoid sheaths (PALS) (Fig. 8). Depletion of the lymphoid follicles was observed in the tonsils of the soft palate (Fig. 9). Lymph node lesions observed were depletion of the germinal centre of the follicles with infiltration of histiocytes and eosinophils at the periphery. Lymph nodes also revealed multifocal areas of granulomatous inflammation with infiltrating epithelioid cells (Fig. 10). Liver showed degeneration of hepatocytes with the infiltration of mononuclear cells in the sinusoidal spaces (Fig. 11). Also, there was occasional sinusoidal and central venous congestion. Kidneys showed variable sized and shrunken glomeruli with moderate to severe degeneration of the tubular epithelial cells. Interstitial nephritis due to the infiltration of mononuclear cells in the renal interstitium was noticed. Non-suppurative myocarditis characterized by the infiltration of mononuclear cells with haemorrhage was observed between the cardiac myofibers.

### Immunohistochemistry

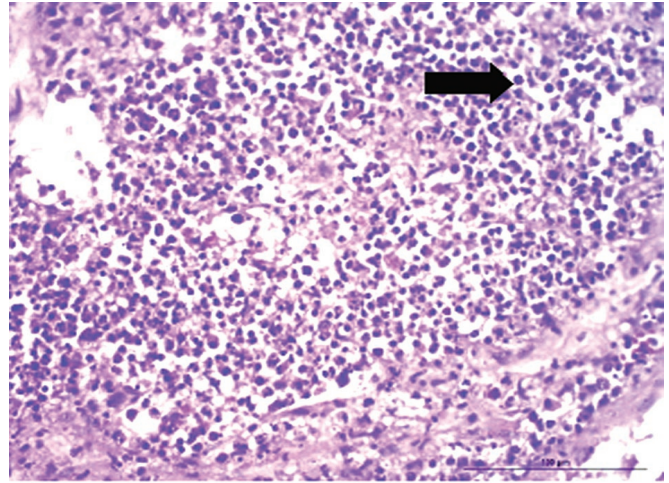
Immunohistochemistry was performed to demonstrate PCV2 antigens in the spleen and lymph nodes of the four positive cases using PCV2 capsid antibody. Positive reaction was identified by typical dark brown reaction

product with DAB as chromogen. Lymph nodes had moderate to strong signals in the follicular region of cortex. Here moderate to strong signals were seen in lymphocytes followed by macrophages while in parafollicular region macrophages showed a more intense brown coloured staining than lymphocytes (Fig. 12). Spleen showed maximum extent of positively stained cells, predominantly in the inter-follicular region. The most consistent staining observed in this region was within the lymphocytes followed by macrophages (Fig. 13). Similarly, lymph nodes showed a higher extent of positively stained cells compared to spleen. Other cells such as reticuloendothelial cells and fibrocytes also revealed mild staining reactions.

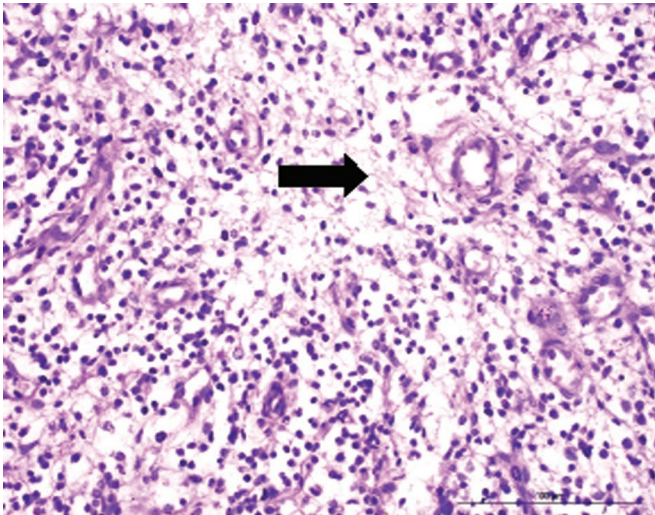
This study mainly involves molecular and pathological studies of PMWS affected piglets followed by concurrent screening for PRRSV and PPV in PMWS positive cases. The carcasses for the present study were selected based on the clinical history and gross lesions. The clinical signs included wasting, respiratory signs, diarrhoea, pallor, icterus were similar to previous reports of PMWS affected pigs (Rosell *et al.* 1999). Gross lesions such as non-collapsed, voluminous lungs with cranio-ventral consolidation, lymphadenopathy, icteric liver and splenomegaly were commonly observed in PCV2 affected piglets. All PCV2 affected piglets were shown pneumonic changes either consolidation mainly in the cranio-ventral lobes or meaty consistency indicating broncho-pneumonia or interstitial pneumonia throughout the lobes. Pneumonic lesions were predominant gross findings in suckling and nursery piglets in PCV2 infection (Szeredi and Szentirmai 2008). Molecular screening revealed four samples positive for PCV2 by conventional PCR using ORF2 specific primer that amplified 481 bp (Ellis *et al.* 1999). These samples were also screened to rule out the possibility of PRRSV and PPV using RT-PCR and PCR respectively. All four samples were also ruled out for PRRSV and PPV concurrent infections. Screening by PCR was reported to be the most rapid and sensitive technique for detecting PCV2 and PPV compared to virus isolation, immunohistochemistry and *in situ* hybridization (Kim and Chae 2004). Similarly, RT-PCR is a better technique for PRRSV identification than virus isolation and *in situ* hybridization methods (Benson *et al.* 2002). Histopathological lesions revealed interstitial and broncho-interstitial pneumonia in all affected piglets. A previous study demonstrated interstitial pneumonia to be the common type of pneumonia in PCV2 affected animals (Tico *et al.* 2013). Lymphoid depletion in the lymphoid organs could be due to the affinity of the virus to immune cells followed by replication and lysis of virus infected



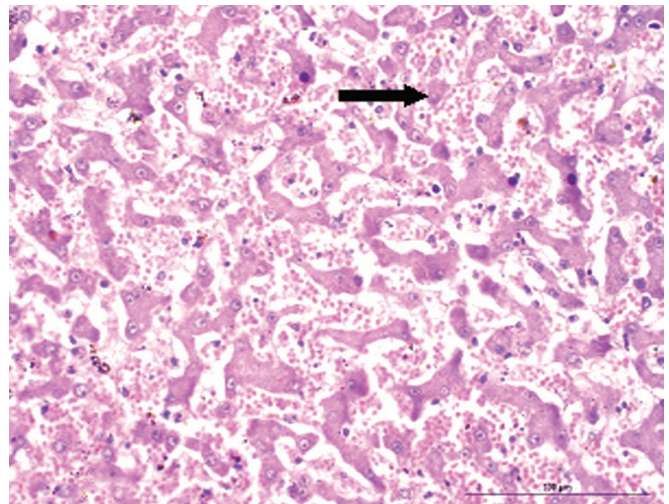
**Fig. 7.** Proliferation of Type II pneumocytes (thick arrow) and congestion of alveolar capillaries (H&Ex400).



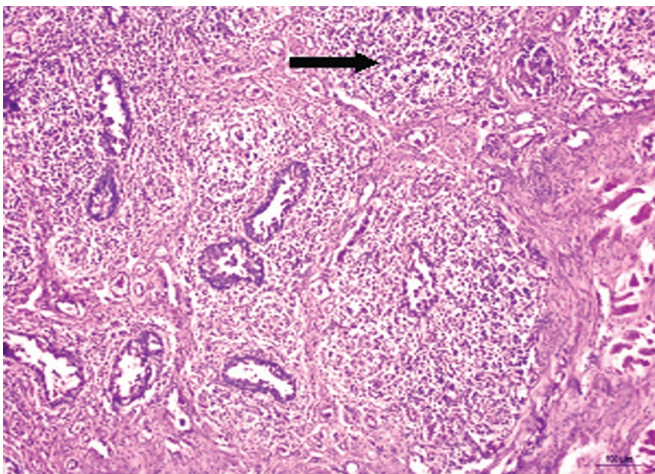
**Fig. 10.** Granulomatous inflammation with infiltration of epithelioid cells in the lymph nodes (thick arrow) (H&Ex400).



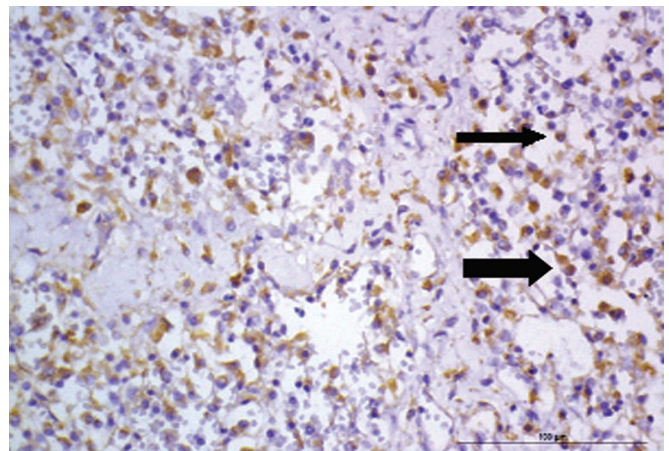
**Fig. 8.** Severe lymphoid depletion of periarteriolar lymphoid sheaths (PALS) in the spleen (thick arrow) (H&Ex400).



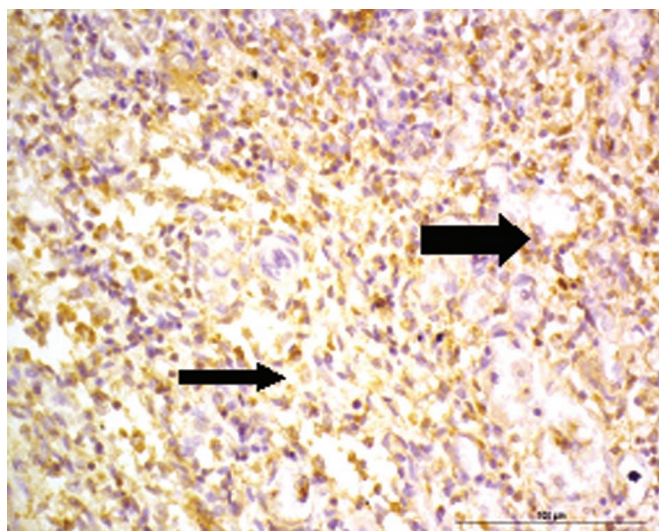
**Fig. 11.** Degenerating hepatocytes (thin arrow) with sinusoidal congestion (H&Ex400).



**Fig. 9.** Depletion of lymphoid follicles in the tonsils of the soft palate (thin arrow) (H&Ex400).



**Fig. 12.** Lymph nodes: Strong PCV2 signals in the macrophages (thick arrow) and lymphocytes (thin arrow) (IHCx400).



**Fig. 13. Spleen: Strong PCV2 signals in the lymphocytes (thin arrow) and macrophages (thick arrow) (IHCx400).**

cells (Ghebremariam and Gruys 2005). There was infiltration of macrophages and eosinophils observed at the periphery of the follicles in the lymph nodes. Presence of eosinophils in the affected lymph nodes could be regarded beneficial as they would release varieties of antiviral and immunoregulatory cytokines (Stevenson *et al.* 2001). In three cases, there was granulomatous inflammation with infiltration of epithelioid cells in the lymph nodes. Another notable lesion recorded in the liver was the mononuclear cell infiltration in portal areas along with moderate degenerative changes in hepatocytes which could be classified as stage I hepatic lesions (Rosell *et al.* 2000). Interstitial nephritis observed might be due to prolonged immunological stimulation towards PCV2 antigens (Drolet *et al.* 2002). Non-suppurative myocarditis was also observed in PCV2 affected pigs as reported in an earlier study (Mikami *et al.* 2005). Demonstration of virus by IHC in association with characteristic microscopic lesions was crucial in establishing a confirmatory diagnosis for PCV2 infections (Segales 2012). Lymph nodes had high intensity of immunohistochemical staining in the lymphocytes of the follicular region, whereas the spleen showed more staining of the macrophages in the interfollicular region. Similar observation was noticed in IHC staining of lymph nodes and spleen in an earlier study (Keerthana *et al.* 2016). The intensity and extent of PCV2 antigen staining in the lymph node were more compared to that in spleen. This might be due to the high replicative nature of PCV2 in the lymph nodes (Kim and Chae 2004). PCV2 demonstration by PCR is not sufficient to establish PMWS (Chae 2003). In order to confirm PMWS, it must meet three requirements *viz.* (1) the

presence of consistent clinical signs (2) the presence of distinctive histopathological changes such as granulomatous inflammation and/or presence of botryoid inclusion bodies (3) demonstration of PCV2 antigens within the lesions (Segales 2012). In this study, the four positive cases were subjected to meet these above conditions. The clinical symptoms reported such as respiratory distress, wasting, diarrhoea, pallor skin or icterus were observed in all four cases (Rosell *et al.* 1999). Out of four cases, three cases had granulomatous inflammation in the lymph nodes. However, botryoid inclusion bodies were not observed in any cases. A previous report in Korea had 97% granulomatous inflammation in PMWS affected pigs and considered it as a useful indicator for diagnosing PMWS as compared to botryoid bodies (Chae 2003). PCV2 was demonstrated within the lesions using IHC revealed presence of PCV2 antigens in spleen and lymph nodes of all cases (Keerthana *et al.* 2016). Among four positive PCV2 cases, three had fulfilled the complete requirement of PMWS. Molecular screening was negative for concurrent infections of PRRSV and PPV in PMWS positive cases. Pathological studies of PMWS in piglets revealed severe respiratory and lymphoid lesions leading to immunosuppression, secondary complications and death of the affected animals.

## CONCLUSION

The present study confirms the incidence of PMWS among piglet population of Kerala. Our findings help the veterinary practitioners to differentially diagnose PCV2 associated lesions for a definitive diagnosis in field cases. As the PCV2 can cause severe immunosuppression in pigs, the role of other co-infecting or opportunistic pathogens should be illustrated. The main limitations of the study were smaller sample size and study had not investigated associated secondary bacterial or fungal infections or other viral pathogens to rule out as a contributing factor in the current cases. Therefore, future studies should be focussed on screening large numbers of samples which could reveal the prevalence of PRRSV and PPV in PMWS affected pigs of Kerala.

## ACKNOWLEDGEMENT

The financial support from Government of Kerala through State Plan Fund 16-17 (RSP/ 16-17/VII-5) and technical support of Kerala Veterinary and Animal Sciences University are greatly acknowledged. The authors are also thankful to the Dean, College of Veterinary and Animal Sciences, Mannuthy for providing the necessary facilities for the study.

## REFERENCES

- Afolabi KO, Iweriebor BC, Obi LC, Okoh AI (2019) Prevalence of porcine parvo viruses in some South African swine herds with background of porcine circovirus type 2 infection. *Acta Tropica* 190: 37-44.
- Aishwarya J, Ravishankar C, Rajasekhar R, Sumod K, Bhaskar N *et al.* (2016) First report of detection and molecular characterization of porcine parvovirus in domestic and wild pigs in Kerala, India. *Virus Dis* 27: 311-314.
- Bancroft JD and Gamble M (2008) *Theory and practice of histopathological techniques*. 6<sup>th</sup> edn. Churchill Livingstone Elsevier, Philadelphia. 725.
- Benson JE, Yaeger MJ, Christopher-Hennings J, Lager K, Yoon KJ (2002) A comparison of virus isolation, immunohistochemistry, fetal serology, and reverse-transcription polymerase chain reaction assay for the identification of porcine reproductive and respiratory syndrome virus transplacental infection in the foetus. *J Vet Diagn Invest* 14: 8-14.
- Chae C (2003) Post weaning multisystemic wasting syndrome: a review of aetiology, diagnosis and pathology. *Vet J* 168: 41-49.
- Drolet R, Ribotta M, Higgins R, D'Allaire S, Larochelle R *et al.* (2002) Infectious agents identified in pigs with multifocal interstitial nephritis at slaughter. *Vet Rec* 150: 139-143.
- Ellis J, Krakowka S, Lairmore M, Haines D, Bratanich A *et al.* (1999) Reproduction of lesions of postweaning multisystemic wasting syndrome in gnotobiotic piglets. *J Vet Diagn Invest* 11: 3-14.
- Ghebremariam M K, Gruys E (2005) Post weaning multi systemic wasting syndrome (PMWS) in pigs with particular emphasis on the causative agent, the mode of transmission, the diagnostic tools and the control measures - a review. *Vet Q* 27: 105-116.
- Hansen MS, Pors SE, Jensen HE, Bille-Hansen V, Bisgaard M *et al.* (2010) An investigation of the pathology and pathogens associated with porcine respiratory disease complex in Denmark. *J Comp Pathol* 143: 120-131.
- Jiang Y, Shang H, Xu H, Zhu L, Chen W *et al.* (2010) Simultaneous detection of porcine circovirus type 2, classical swine fever virus, porcine parvovirus and porcine reproductive and respiratory syndrome virus in pigs by multiplex polymerase chain reaction. *Vet J* 183: 172-175.
- Keerthana J, Abraham MJ, Krithiga K, Priya PM, Nair D (2016) Pathological and immunopathological studies on naturally infected cases of porcine circovirus 2 in Kerala. *Indian J Livestock Res* 12: 81-86.
- Kim J, Chae C (2004) A comparison of virus isolation, polymerase chain reaction, immunohistochemistry, and *in situ* hybridization for the detection of porcine circovirus 2 and porcine parvovirus in experimentally and naturally coinfecting pigs. *J Vet Diagn Invest* 16: 45-50.
- Kumar GS (2008) Porcine circovirus-2 associated diseases. *Ind J Vet Pathol* 32: 135-142.
- Mikami O, Nakajima H, Kawashima K, Yoshi M, Nakajima Y (2005) Non-suppurative myocarditis caused by porcine circovirus type 2 in a weak-born piglet. *J Vet Med Sci* 67: 735-738.
- Neira V, Ramos N, Tapia R, Arbiza J, Neira-Carrillo A (2017) Genetic analysis of porcine circovirus type 2 from pigs affected with PMWS in Chile reveals intergenotypic recombination. *Virol J* 14: 191.
- Ouyang T, Zhang X, Liu X, Ren L (2019) Co-infection of swine with porcine circovirus type 2 and other swine viruses. *Viruses* 11(2): 185.
- Pallares FJ, Halbur PG, Opriessnig T, Sorden SD, Villar D (2002) Porcine circovirus type 2 (PCV-2) coinfections in US field cases of post weaning multi systemic wasting syndrome (PMWS). *J Vet Diagn Invest* 14: 515-519.
- Rosell C, Segales J, Plana-Duran J, Balasch M, Rodriguez-Arriola GM *et al.* (1999) Pathological, immunohistochemical, and *in situ* hybridization studies of natural cases of postweaning multisystemic wasting syndrome (PMWS) in pigs. *J Comp Pathol* 120: 59-78.
- Rosell C, Segales J, Domingo M (2000) Hepatitis and staging of hepatic damage in pigs naturally infected with porcine circovirus type 2. *Vet Pathol* 37: 687-692.
- Segales J (2012) Porcine circovirus type 2 (PCV2) infections: clinical signs, pathology and laboratory diagnosis. *Virus Res* 164: 10-19.
- Stevenson GW, Kiupel, M, Mittal SK, Choi J, Latimer KS *et al.* (2001) Tissue distribution and genetic typing of porcine circoviruses in pigs with naturally occurring congenital tremors. *J Vet Diagn Invest* 13: 57-62.

Szeredi L, Szentirmai C (2008) Proliferative and necrotising pneumonia and severe vascular lesions in pigs naturally infected with porcine circovirus type 2. *Acta Vet Hung* 56: 101-109.

Tico G, Segales J, Martinez J (2013) The blurred border between porcine circovirus type 2-systemic disease and porcine respiratory disease complex. *Vet Microbiol* 163: 242-247.

Vargas FD, Escatell GAS, Lara ACMI, Salas MEC, Cruz JRS (2018) Study of porcine circovirus type 2 (PCV2) and porcine reproductive and respiratory syndrome virus (PRRSV) frequencies and coinfection in Mexican farrow to finish pig farms. *J Vet Med Anim Health* 10: 96-100.

**\*Cite this article as:** Sairam R, Krishna BD, Krithiga K, Sajitha IS, Priya PM, Ravishankar C, Abraham MJ (2019) Molecular and pathological studies of post-weaning multi-systemic wasting syndrome among piglets in Kerala, India. *Explor Anim Med Res* 9(2): 137-144.